



EFFICACY OF OLMESARTAN, IRBESARTAN AND TELMISARTAN AGAINST ACUTE INDOMETHACIN-INDUCED GASTRIC ULCERS IN MICE

Sara Khallouf^{1*}, Rana Makhous¹ and Rana Issa²

¹Pharmacology & Toxicology Department, Faculty of Pharmacy, Tishreen University, Lattakia, Syria

²Pathology Department, Faculty of Medicine, Tishreen University, Lattakia, Syria

Recent studies have determined detrimental effects of angiotensin-II in gastric mucosa. This study aims to investigate the gastroprotective role of some Angiotensin-II receptor blockers (ARBs): olmesartan, irbesartan and telmisartan on indomethacin-induced gastric ulcers in mice. Also, it provides a new comparison to know if the agonist action of peroxisome proliferator-activated receptor gamma (PPAR- γ) involves in protecting gastric mucosa; if found. Animals were divided into six groups ($n=9$ in each); group 1 (normal control), group 2 (non-pretreated, induced-ulcer), group 3 (olmesartan 8.2 mg/kg), group 4 (irbesartan 61.5 mg/kg), group 5 (telmisartan 16.4 mg/kg), group 6 (ranitidine 61.5 mg/kg). Drugs were given orally for 15 days; then gastric ulcers were induced by a single oral dose of indomethacin (250 mg/kg). Histological findings showed that these members of ARBs decreased the depth of ulcers but without significant difference between them. Their gastroprotective effects were not comparable to ranitidine effect. We need further researches, and recommend studying the effect of ARBs in combination with anti-ulcer drugs.

Keywords: angiotensin-II; gastroprotective; ARBs; PPAR- γ ; gastric ulcers; indomethacin

INTRODUCTION

Peptic ulcer, whether gastric or duodenal, is a common disease affecting about 5-10% of people in the world^{1&2}. It occurs when the balance between defensive and aggressive factors is disturbed³. It is described as a gastric mucosal erosions that are extended through the muscularis mucosa^{2&4}.

Angiotensin-II is the main product of renin-angiotensin system. It has crucial effects in regulating blood pressure and controlling of fluids and electrolytes in the body⁵.

Recently, high concentrations of renin and angiotensin-II were observed in ulcerated gastric tissues of rats⁶. Also, many researchers reported that angiotensin-II has detrimental effects in gastric mucosa. It reduces blood flow and induces inflammatory cascades and oxidative stress⁷. This suggests a possible role of angiotensin-II in the pathogenesis of gastric ulcers.

Angiotensin-II receptor blockers (ARBs) are antihypertensive drugs that selectively act by blocking AT₁ receptors. These drugs possess partial peroxisome proliferator-activated receptor gamma (PPAR- γ) agonistic actions. These properties vary between ARBs depending on lipophilicity⁸.

Many studies have indicated a benefit of these drugs in prevention of gastric ulcers. They suggested a difference in the gastroprotective role of ARBs, and it was attributed to PPAR- γ agonist actions.^{7&9-12}

This study aims to investigate the efficacy of these drugs in prevention of indomethacin-induced gastric ulcers in mice. Also, it provides new comparison between three members of ARBs: telmisartan (the highest partial PPAR- γ agonist), irbesartan (a less potent PPAR- γ agonist) and olmesartan (the least potent PPAR- γ agonist)¹³. This helps to know the role of agonist action of PPAR- γ in protecting gastric mucosa. Therefore, we can determine

the best drug for patients who have high blood pressure with gastric ulcers.

MATERIALS AND METHODS

Drugs

Telmisartan, irbesartan, olmesartan, ranitidine and indomethacin were obtained from Syrian pharmaceutical factories. Indomethacin was suspended in 1% aqueous solution of carboxymethyl cellulose (CMC). Other drugs were dissolved in 0.5% aqueous solution of CMC. All solutions were prepared freshly.

Animals

This experiment was carried out using 54 Balb/c male mice weighing between 20-30 g. The mice were purchased from the Scientific Research Center, Damascus, Syria. They were acclimatized for two weeks before starting the experiment. The animals were kept at controlled environmental conditions (temperature 25 ± 2 °C, humidity $50 \pm 15\%$, under a 12 hrs. light/dark cycle). They had free access to standard mice diet and water. All methods performed in this study were in accordance with the regulatory guidance of the care and use of experimental animals. The Scientific Research Ethics Committee at Tishreen University gave us the ethical approval for this study, after reviewing all stages of work.

Experimental protocol

Animals were divided into six groups (n=9 in each group).

- **Group 1.** (normal group): received oral vehicle (CMC 0.5% solution).
- **Group 2.** (indomethacin group): received oral vehicle (CMC 0.5% solution).
- **Group 3.** (olmesartan group): received olmesartan (8.2 mg/kg).
- **Group 4.** (irbesartan group): received irbesartan (61.5 mg/kg).
- **Group 5.** (telmisartan group): received telmisartan (16.4 mg/kg).
- **Group 6.** (ranitidine group): received ranitidine (61.5 mg/kg).

Drugs and vehicle were given orally daily for 15 days. The doses were calculated depending on Human Equivalent Dose (HED)¹⁴.

Ulcer induction and gastric tissue collection

After 15 days, the mice were fasted from food with free access to drinking water for 16 hrs. All mice were given indomethacin in a single oral dose (250 mg/kg), except for the first group which was given an equivalent amount of CMC 1%. The dose of indomethacin was tested before starting work. It was consistent with that used by Timoshin *et al*¹⁵. All experiments were performed during the same time of the day to avoid diurnal variations of the putative regulators of gastric functions. The mice were sacrificed 6 hrs following indomethacin administration by an overdose of ether. Each stomach was removed and opened along the greater curvature (**Error! Reference source not found.**). The stomachs were washed with saline solution, then were fixed in formalin 10% solution for histopathological examination.

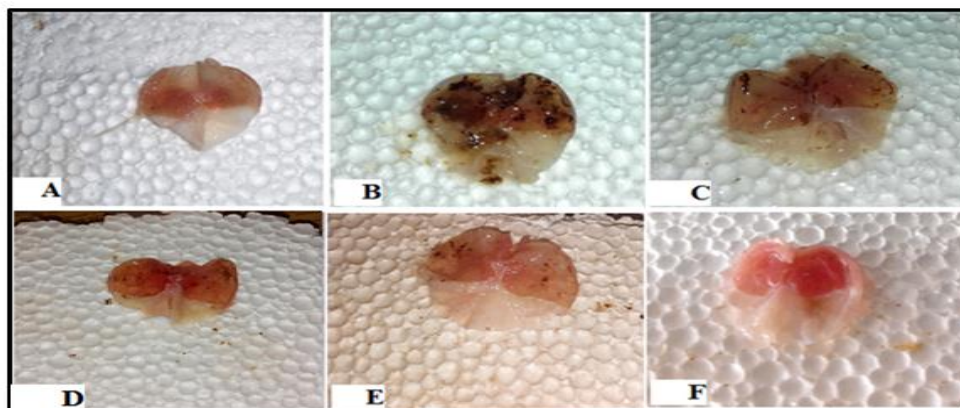


Fig. 1 : Macroscopic morphology changes in the gastric mucosa. A, normal group; B, indo group; C, olme-pretreated group; D, irbe-pretreated group; E, telmi-pretreated group; F, rani-pretreated group.

Histopathological examination of gastric tissue

Formalin-fixed tissues were dehydrated in ascending grades of alcohol and embedded in paraffin. Sections of 5- μ m thickness taken, stained with hematoxylin and eosin (H&E) and examined by light microscopy by a pathologist unaware of the treatment protocol. The ulcers were scored for intensity on a scale of 0-4 (Table 1).

Table 1: scoring system

Score	normal gastric mucosa
0	superficial erosions of mucosa
1	medium depth lesions of mucosa
2	deep lesions of mucosa without crossing the muscularis mucosa
3	ulcers which are extended through muscularis mucosa
4	normal gastric mucosa

• Ulcer Index & Protective Ratio

Gastric mucosal lesions were expressed in terms of the ulcer index according to the method of Desai *et al*¹⁶. The ulcer index (UI) was calculated from the equation:

Ulcer Index (UI) = mean of intensity in a group + [number of ulcer positive animals/total number of animals] \times 2

The percentage protective ratio was calculated from the equation¹⁷:

Protective ratio = [1 - (UI pretreated group/ UI indo group)] \times 100

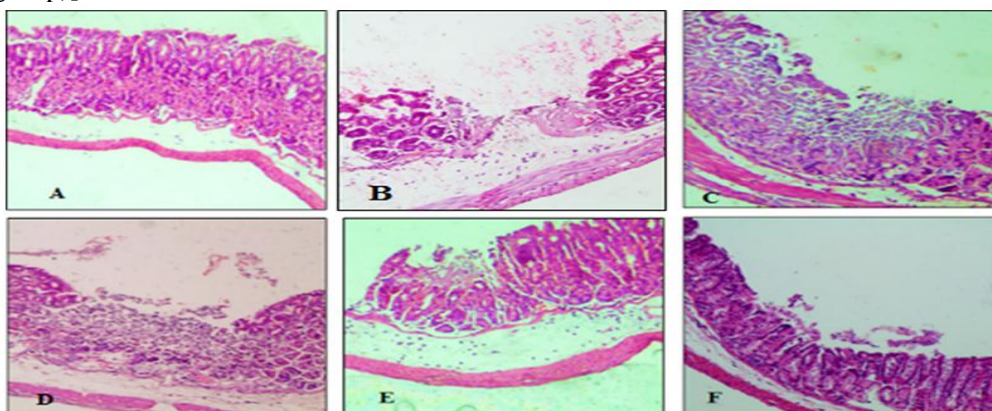


Fig. 1: Histological assessment of gastric tissues using H&E stain. (A) normal group showed normal mucosa without any ulcer. (B) indo group showed deep ulcers which are extended through muscularis mucosa. (C, D, E) olme, irbe, telmi groups respectively showed medium depth lesions of mucosa without extending through muscularis mucosa. (F) rani group showed superficial erosions of mucosa.

Statistical analysis

Data analyses were performed using SPSS software package (version 26). Data were presented as means \pm SD. Different groups were compared using one-way analysis of variance (ANOVA) followed by the Least Significant Difference (LSD) test and Dunnett's test for multiple comparisons. $P < 0.05$ was selected as the criterion for statistical significance.

RESULTS AND DISCUSSION

Results

Histopathological study

In normal group, we observed some congestion of blood vessels, but the gastric epithelium was normal without any erosions (Fig. 1 A).

The administration of indomethacin caused deep ulcers which were extended through muscularis mucosa. Also, inflammatory infiltrates were noted (Fig. 1 B).

The pretreatment with olmesartan, irbesartan and telmisartan reduced the depth of lesions. We observed medium depth lesions without crossing the muscularis mucosa. some inflammatory infiltrated cells were noted (Fig. 1 C,D,E).

In ranitidine group, the mucosa was protected from ulcers. We saw very superficial erosions in the epithelium without presence of the pathological changes seen in indomethacin group (Fig. 1 F).

Effect of ARBs on ulcer score, ulcer index and protective ratio in indomethacin induced gastric ulcers

The pretreatment with olmesartan, irbesartan and telmisartan showed significant reduction in ulcer score when compared to indomethacin group. There were a statistically

significant differences in ulcer score in olmesartan, irbesartan, and telmisartan groups when compared to rani group ($P < 0.05$). The ulcer score of telmisartan group was lower than those of irbesartan and olmesartan groups but without statistical significance ($P > 0.05$) (**Error! Reference source not found.**, Fig. 2).

Table 2: Effect of olmesartan, irbesartan, telmisartan on indomethacin induced ulcers.

parameter	Ulcer score Mean \pm SD	Ulcer index	Protective ratio
group			
Normal	0.00 \pm 0.00	0.00	-----
Indo	3.89 \pm 0.33 @	5.67	-----
Olme	2.71 \pm 1.11* #	3.29	42.02 %
Irbe	2.67 \pm 0.71 * #	2.89	49.02 %
Telmi	2.25 \pm 0.89 * #	2.25	60.29 %
Rani	1.11 \pm 0.33 *	1.11	% 80.39

@P < 0.05 when compared to normal group.
*P < 0.05 when compared to indo group.
#P < 0.05 when compared to rani group.

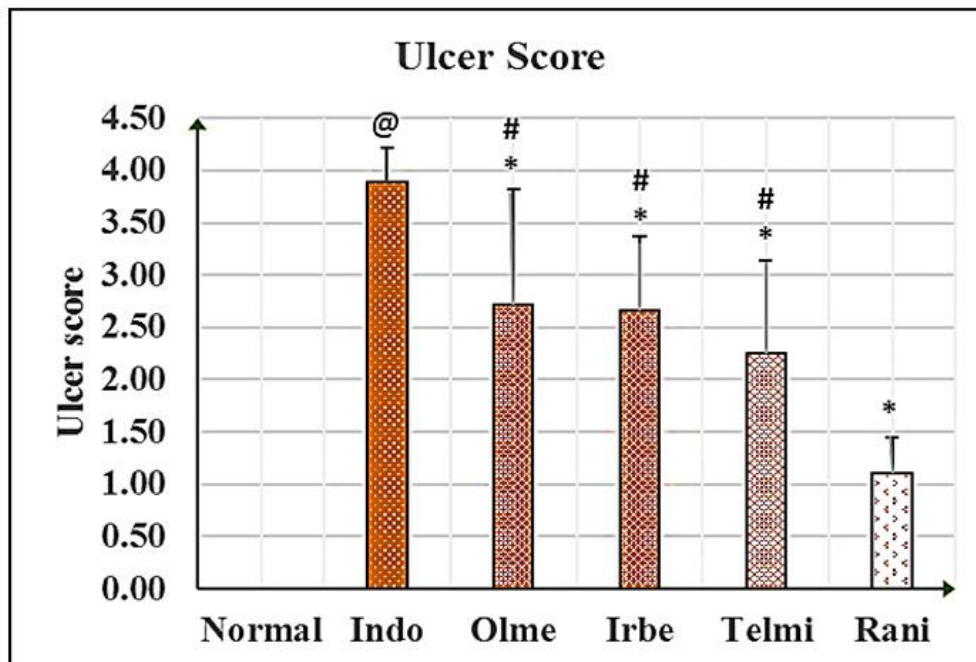


Fig. 2: Ulcer score. @P < 0.05 compared to normal group, *P < 0.05 compared to indo group, #P < 0.05 compared to rani group. Data were expressed as Mean \pm SD.

Discussion

In this study, mice developed acute gastric ulcers when given a single oral dose of indomethacin and this was expected. Indomethacin is the drug of choice for experimental ulcer model induction. It is superior in this property to the other NSAIDs¹⁸. Pathological mechanisms include: increasing acid secretion, decreasing mucus and bicarbonate synthesis, reducing mucosal blood flow, releasing inflammatory mediators and free radicals and direct local mechanisms¹⁹⁻²². Our study showed that the pretreatment with olmesartan, irbesartan and telmisartan protected the gastric mucosa from deep ulcers formation. This was consistent with many studies which suggested a gastroprotective properties of these drugs^{9-12&23&24}.

According to previous studies, these drugs maintain blood flow to the gastric mucosa by inhibiting vasoconstriction mediated by AT₁ and decreasing sympathoadrenal activation²⁵. Also, they suppress acid secretion by increasing NO release and decreasing phosphorylated extracellular signal-regulated kinase 1 and 2 (pERK1/2). These drugs have antioxidant and anti-inflammatory properties in gastric mucosa due to AT₁ blocking and PPAR- γ stimulating^{9&11&12&26}.

Olmesartan, irbesartan and telmisartan have variant efficacy in stimulating of PPAR- γ . A previous study suggested a gastroprotective effect of PPAR- γ agonists²⁷.

However, in our study, these three drugs did not show a significant difference in their effects on gastric mucosa. Since PPAR- γ stimulating did not make a difference, we may can say that the gastroprotective role of olmesartan, irbesartan and telmisartan is due to their primary effects as AT₁ receptors antagonists.

This result is in contrast with the study that suggested the superiority of telmisartan over olmesartan because it is the highest partial PPAR- γ agonist¹². As for irbesartan, this is the first study that compare its effectiveness with telmisartan and olmesartan.

Ranitidine was used as a reference drug. We found that the protective effect of these members of ARBs was less than and not comparable to ranitidine effect.

This result, about telmisartan, is consistent with this of Suvarna *et. al.*²⁴, but it contradicts the study of Mohamed *et. al.*¹¹.

As for irbesartan, Nancy *et. al* found that its efficacy was comparable to ranitidine effect⁹, and this is inconsistent with our findings.

There is not any study that compared the gastroprotective effect of olmesartan with ranitidine and this is the first one.

Conclusion

The present findings demonstrate that pretreatment by olmesartan, irbesartan and telmisartan protected mice's gastric mucosa against indomethacin-induced ulcers. These effects were not as ranitidine effect. Olmesartan, irbesartan and telmisartan did not show any superiority in their protective effects. This is the first study that compares the gastroprotective effects of these drugs. However, we need further researches. We recommend studying the effect of ARBs in combination with anti-ulcer drugs to investigate if there is a synergistic gastroprotective effect.

REFERENCES

1. S. Sumbul, M. A. Ahmad, A. Mohd and A. Mohd, "Role of phenolic compounds in peptic ulcer: an overview", *Journal of Pharmacy and Bioallied Sciences*, 3(3), 361, 1-7 (2011).
2. A. Kanjarawe, A. Alish and M. Saied, "Surgical treatment of peptic ulcer (Surgical methods followed at Alasad university hospital in Lattakia)", *Tishreen University Journal For Research and Scientific Studies - Health Sciences Series*, 39(3), 267-286 (2017).
3. C. Serafim, M. E. Araruna, E. A. Júnior, M. Diniz, C. Hiruma-Lima, *et al.*, "A review of the role of flavonoids in peptic ulcer (2010–2020)", *Molecules*, 25(22), 5431(2020).
4. M. Drini, "Peptic ulcer disease and non-steroidal anti-inflammatory drugs", *Australian Prescriber*, 40(3), 91-93 (2017).
5. T. Brzozowski, "Role of renin–angiotensin system and metabolites of angiotensin in the mechanism of gastric mucosal protection", *Current Opinion in Pharmacology*, 19, 90-98 (2014).
6. Z. Halici, B. Polat, E. Cadirci, A. Topcu, E. Karakus, *et al.*, "Inhibiting renin angiotensin system in rate limiting step by

- aliskiren as a new approach for preventing indomethacin induced gastric ulcers", *Chemico-Biological Interactions*, 258,266-275(2016).
7. R. Kamel, E. M. El Morsy and A. S. Awad, "Immunomodulatory effect of candesartan on indomethacin-induced gastric ulcer in rats", *Immunopharmacology and Immunotoxicology*, 34(6), 956-961 (2012).
 8. M. C. Michel, C. Foster, H. R. Brunner and L. Liu, "A systematic comparison of the properties of clinically used angiotensin II type 1 receptor antagonists", *Pharmacological Reviews*, 65(2), 809-848 (2013).
 9. N. Shahin; N. Abdelkaderm and M. Safar, "A novel role of irbesartan in gastroprotection against indomethacin-induced gastric injury in rats: targeting DDAH/ ADMA and EGFR/ERK signaling", *Scientific Reports*, 8(1), 1-12 (2018).
 10. A. Fouad, A. I. Al-Sultan, M. Yacoubi and W. Gomaa, "Ameliorative effects of telmisartan in diabetic rats with indomethacin-induced gastric ulceration", *European Journal of Pharmacology*, 637(1-3), 162-170 (2010).
 11. M. Morsy, O. Ashr, E. Amin and R. Rofaeil, "Gastroprotective effects of telmisartan on experimentally-induced gastric ulcers in rats", *Pharmazie*, 64(9), 590-594 (2009).
 12. M. K. Tawfik, "protective role of telmisartan, candesartan and olmesartan on cold restraint stress -induced gastric ulcer in rats: influence of PPAR γ mRNA", *Al-azhar Journal of Pharmaceutical Sciences*, 45, 365-382 (2012).
 13. S. C. Benson, H.A. Pershadsingh, C. I Ho, A. Chittiboyina, P. Desai, *et al.*, "Identification of telmisartan as a unique angiotensin II receptor antagonist with selective PPAR γ -modulating activity", *Hypertension*, 43(5), 993-1002 (2003).
 14. A. B. Nair and S. Jacob, "A simple practice guide for dose conversion between animals and human", *Journal of Basic and Clinical Pharmacy*, 7(2), 27-31 (2016).
 15. S. Timoshin, V. Bragina, O. Lebedko, E. Sazonova, E. Y. Zhivotova, *et al.*, "Effect of HMG-CoA-reductase inhibitor on DNA synthesis and free radical oxidation in the gastric mucosa under normal conditions and during indometacin-induced ulcerative process in the stomach of albino mice", *Bulletin of Experimental Biology and Medicine*, 152(3), 298-300 (2012).
 16. J. K. Desai, R. K. Goyal and N. S. Parmar, "Characterization of dopamine receptor subtypes involved in experimentally induced gastric and duodenal ulcers in rats", *Journal of Pharmacy and Pharmacology*, 51(2), 187-192 (1999).
 17. S. Simões, R. Lopes, M. C. D. Campos, M. J. Marruz, M. E. M. Mda Cruz, *et al.*, "Animal models of acute gastric mucosal injury: Macroscopic and microscopic evaluation", *Animal Models and Experimental Medicine*, 2(2), 121-126 (2019).
 18. H. Suleyman, A. Albayrak, M. Bilici, E. Cadirci and Z. Halici, "Different mechanisms in formation and prevention of indomethacin-induced gastric ulcers", *Inflammation*, 33(4), 224-234 (2010).
 19. M. Fornai, L. Antonioli, C. Rocchina, T. Marco and C. Blandizzi, "Pathophysiology of gastric ulcer development and healing: molecular mechanisms and novel therapeutic options", (2011).
 20. C. Gunaydin and S. S. Bilge, "Effects of nonsteroidal anti-inflammatory drugs at the molecular level", *The Eurasian Journal of Medicine*, 50(2), 116-121 (2018).
 21. B. J. Whittle, "Gastrointestinal effects of nonsteroidal anti- inflammatory drugs", *Fundamental & Clinical Pharmacology*, 17(3), 301-313 (2003).
 22. M. Intaneus, I. Hammad and A. Ahmad, "Upper Gastrointestinal Bleeding Stimulated By Non Steroidal Anti Inflammatory Drugs", *Tishreen University Journal -Medical Sciences Series*, 31, 193-207 (2009).
 23. C. Bregonzio, I. Armando, H. Ando, M. Jezova, G. Baiardi, *et al.*, "Angiotensin II AT1 Receptor Blockade Prevents Gastric Ulcers during Cold-Restraint Stress",

- Annals New York Academy of Sciences*, 1018, 351-355 (2004).
24. S. S. Rathod, V. M. Motghare and V. S. Deshmukh, "Study of antiulcer activity of angiotensin receptor antagonists in experimentally induced gastric ulcers in rats", *International Journal of Pharmaceutical Sciences and Research*, 5, 502-507 (2014).
 25. C. Bregonzio, I. Armando, H. Ando, M. Jezova, G. Baiardi, *et al.*, "Anti-inflammatory effects of angiotensin II AT1 receptor antagonism prevent stress-induced gastric injury", *Am J Physiol Gastrointest Liver Physiol*, 285(2), 414-423 (2003).
 26. A. Berg, S. Redéen, M. Grenegard, A. -C. Ericson, and S. E. Sjostrand, "Nitric oxide inhibits gastric acid secretion by increasing intraparietal cell levels of cGMP in isolated human gastric glands", *American Journal of Physiology-Gastrointestinal and Liver Physiology*, 289(6), G1061-G1066 (2005).
 27. Y. Naito, T. Takagi and T. Yoshikawa, "Gastrointestinal cytoprotection by PPAR γ ligands", *PPAR Research*, 2010, 1-8 (2010).



نشرة العلوم الصيدلانية جامعة أسيوط



تقييم فعالية الأولميسارتان، الإربيسارتان، والتيلميسارتان ضد قرحات المعدة الحادة المُحدثة بالإندوميتاسين لدى الفئران البحث

سارة خلوف^{١*} - رنا مخوس^١ - رنا عيسى^٢

^١ قسم الأدوية والسموم، كلية الصيدلة، جامعة تشرين، اللاذقية، سوريا

^٢ قسم علم الأمراض، كلية الطب، جامعة تشرين، اللاذقية، سوريا

رصدت دراسات حديثة تأثيرات مؤذية للأنجيوتنسين-٢ على مستوى الجدار المخاطي المعدي، لذلك تهدف هذه الدراسة للتقصي عن فعالية بعض حاصرات مستقبلات الأنجيوتنسين-٢ (الأولميسارتان، الإربيسارتان، والتيلميسارتان) في الوقاية من القرحة المعدية المحرّضة بالإندوميتاسين لدى فئران التجربة. يقدّم هذا البحث أيضاً مقارنة جديدة لمعرفة فيما إذا كان للفعل الشداد لمستقبلات peroxisome proliferator-activated receptor gamma (PPAR- γ) دوراً في هذا الفعل الوقائي إن وُجد.

قسمت الفئران إلى ٦ مجموعات (ن=٩ في كل مجموعة): مجموعة شاهدة طبيعية، مجموعة شاهدة مرضية، مجموعات عولجت مسبقاً بالأولميسارتان، الإربيسارتان، والتيلميسارتان على الترتيب، ومجموعة عولجت بالرانيتيدين كدواء مرجعي مضاد للقرحة. استمرت المعالجة لمدة ١٥ يوماً عبر الفم، ثم حُرّضت القرحة بجرعة فموية وحيدة من الإندوميتاسين (٢٥٠ ملغ/كغ).

أظهرت نتائج الفحص النسيجي أن هذه الأدوية قللت من عمق التقرحات الحاصلة، لكن دون وجود فرق مهم فيما بينها، كما أن هذه الفعالية الوقائية لم تكن كفعالية الرانيتيدين.

لا يزال هذا الموضوع بحاجة إلى المزيد من التقصي والدراسة، كما نوصي بتقييم الفعل الوقائي لهذه الأدوية بالمشاركة مع الرانيتيدين، لربما تظهر فعلاً تآزرياً في الوقاية من القرحة الهضمية.